

Evaluation of Tomosynthesis Using SONIALVISION safire Digital Table

– Based on Presentation by Dr. Flynn of Henry Ford Health System at RSNA 2006–

Medical Systems Division, Shimadzu Corporation

Tetsuo Imanishi

1. Introduction

Henry Ford Health System (HFHS, **Fig. 1**) in the USA and Shimadzu Corporation have been conducting collaborative research into the clinical evaluation of tomosynthesis using a SONIALVISION safire digital table equipped with a 17-inch direct-conversion flat panel detector.

Dr. Flynn of HFHS presented the results of this collaborative research at RSNA 2006 held by the Radiological Society of North America in December 2006 and many visitors were able to see the associated clinical images in the Henry Ford Health System Corner in the Shimadzu booth. These clinical images were also presented at an educational symposium held by the SEAAPM (Southeast Chapter of the American Association of Physicists in Medicine) in March 2007.

1.1. History of the Henry Ford Health System

Henry Ford, the founder of the Ford Motor Company, established the Henry Ford Health System in Detroit as a philanthropic enterprise in 1915. It is a sophisticated medical center offering 903 beds that also provides training and research opportunities. HFHS has a close relationship with the School of Medicine at Wayne State University in Detroit and conducts training for Michigan State University junior and senior medical students on rotations through each department. HFHS conducts heart, lung, kidney, liver and other transplant surgeries and is ranked by medical journals amongst the top hospitals in the USA.

Henry Ford Health System and Shimadzu Corporation began collaborative research into the clinical evaluation of tomosynthesis using digital radiography in April 2006. Shimadzu provides support with equipment and research.

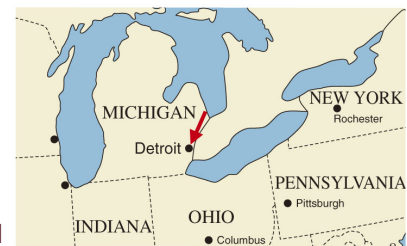

Fig. 1

2. Physical Performance of a General Radiographic Tomosynthesis System With a Selenium DR Detector (RSNA 2006)

Dr. Michael Flynn of HFHS is an extremely well-known radiation physicist in the USA. At RSNA 2006, he gave a presentation entitled, "Physical Performance of a General Radiographic Tomosynthesis System With a Selenium DR Detector." (**Fig. 2**)

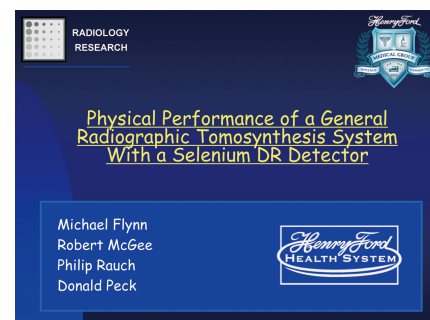


Fig. 2

2.1. Features of SONIALVISION safire

Fig. 3 shows the features of the Shimadzu SONIALVISION safire. The SONIALVISION safire digital table features high resolution, low geometric distortion, high frame rate, and extremely low lag. It was judged to offer the high-precision movements of mechanical components essential for high-accuracy tomosynthesis.

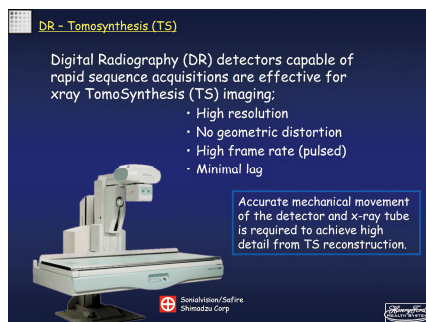


Fig. 3

2.2. Acquisition Conditions and safire Specifications

Fig. 4 shows the movements during tomosynthesis. For lateral radiography of the knee joint, a 60° table tilt angle is used and the X-ray tube and FPD move in opposition. The X-ray tube swing angle is $\pm 20^\circ$. Tomosynthesis for clinical evaluation of the knee joint was conducted with 75 views acquired over 2.5 s at 30 fps frame rate under X-ray conditions of 65 kV to 70 kV and 1 mAs X-ray dose per frame. The entrance exposure is estimated at 216 mR, which is about one-fifth the dose from a multislice CT exam.

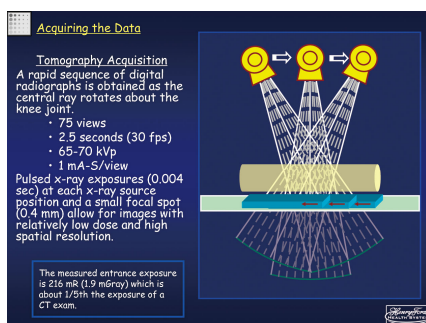


Fig. 4

Fig. 5 shows the specifications for the 17-inch FPD.

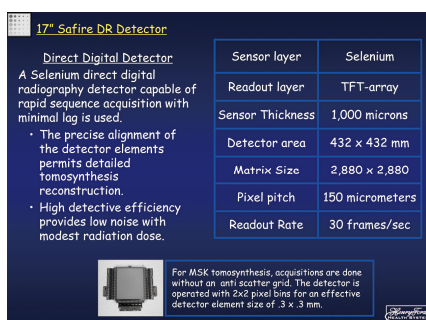


Fig. 5

Fig. 6 shows a graph of the spatial resolution characteristics of the detector. As the detector is a direct-conversion FPD, the measured characteristics (solid line) are extremely close to the ideal characteristics (broken line). Dr. Flynn explained that the measured curve was believed to be slightly lower due to MTF deterioration resulting from secondary X-rays generated in the conversion layer. The results from Monte Carlo simulations conducted in the past matched the measured results. The noise characteristics exhibited at least two times the DQE of other manufacturers' direct-conversion FPDs for radiography. Also, due to the low level of scattered X-rays, tomosynthesis examinations of the knee joint are conducted with the X-ray grid removed.

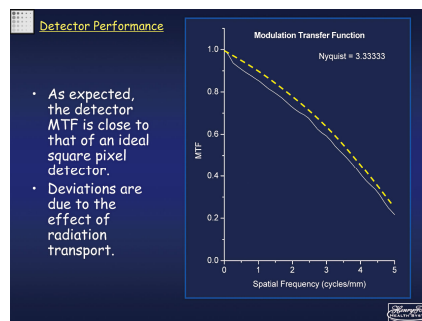


Fig. 6

2.3. Principle of Tomosynthesis Reconstruction

Fig. 7 shows the principle of tomosynthesis reconstruction. While reconstruction is similar to cone-beam CT, due to the restricted projection angle, the data is effective only in the shaded area of the spatial frequency domain, and a limiting filter is applied to the Z-direction frequency.

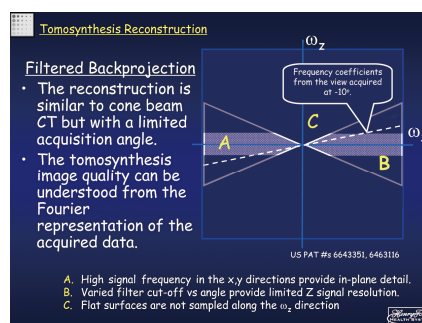


Fig. 7

2.4. Evaluation of the FPD Transient Response

The FPD transient response was evaluated by conducting tomosynthesis on a 1.51 mm copper plate using RQA5 equivalent radiation quality and measuring the pixel value while moving across the edge of the copper plate. (**Fig.8**)

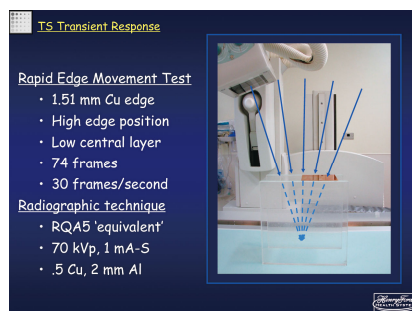


Fig. 8

Graphs of the pixel value in each frame plotted while moving from light to dark and from dark to light indicate the excellent lag characteristics of the Shimadzu FPD. (Fig. 9)

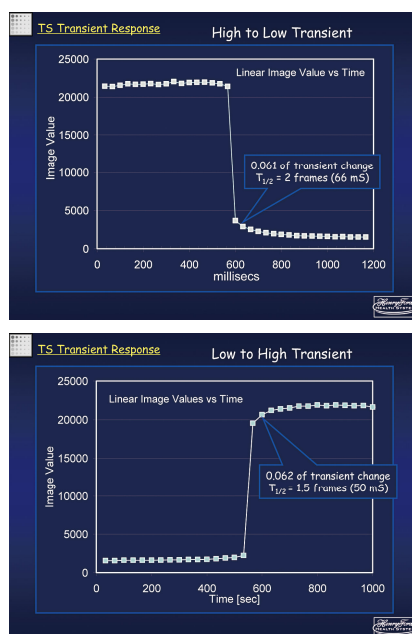


Fig. 9

2.5. Measuring Slice Thickness and Spatial Resolution

The slice thickness and spatial resolution were measured using a test phantom (Fig.10). The phantom comprises an 80 μm tungsten wire inclined at 1:10 pitch, which is an angle of about 6 degrees.




Fig. 10

The tungsten wire is 80 μm thick and the FPD pixel size is 300 \times 300 μm max. with 2 \times 2 binning. A magnified image is shown in Fig. 11.




Fig. 11

Fig.12 shows the tomosynthesis image of the tungsten wire. The image was reconstructed with a 1 mm slice interval. The tomographic slice thickness was measured as approximately 2.5 mm from the FWHM of the profile along the tungsten wire.




Fig. 12

In addition, the profile perpendicular to the tungsten wire in the tomosynthesis image of the tungsten wire (Fig. 13) yields FWHM = 0.238 mm.

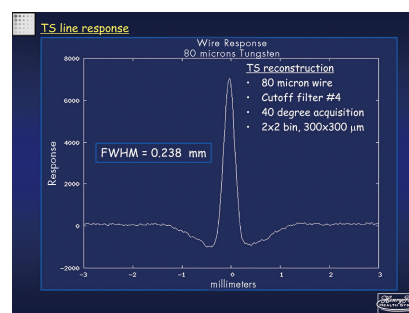


Fig. 13

Normally, the Modulation Transfer Function (MTF) curve is the Fourier transform of the line spread function. However, a feature of this method is the loss of DC components due to effects of filtered backprojection (Fig. 14).

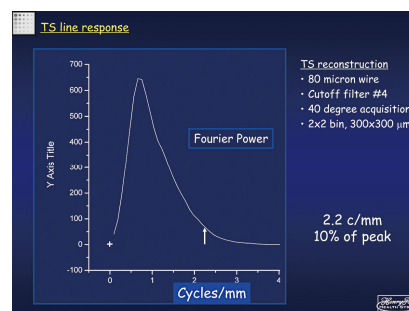


Fig. 14

3. Clinical Images in the Henry Ford Health System Corner at RSNA 2006

The Henry Ford Health System Corner in the Shimadzu booth introduced actual examination techniques, based on a display of clinical images of tomosynthesis of the weight-bearing knee.

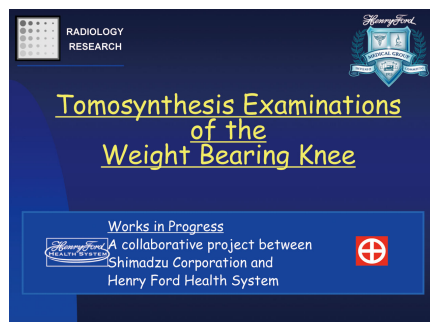


Fig. 15

3.1. Osteoarthritis of the Knee in the USA

Fig. 16 describes the status of knee osteoarthritis in the USA. Symptomatic knee osteoarthritis occurs in over 6% of adults over the age of 30 and in 12% over the age of 60. Standing knee radiographs are commonly used to diagnose knee osteoarthritis. However the small insufficiency fractures (cracks) that lead to future severe osteoarthritis are particularly difficult to assess in conventional radiographs.

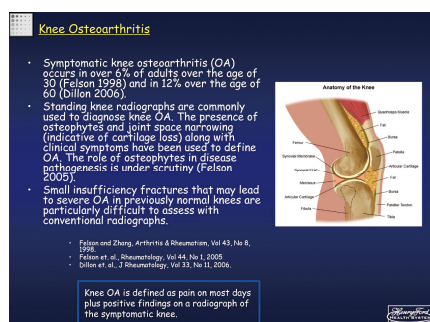


Fig. 16

3.2. Knee Examinations

Fig. 17 shows the situation during weight-bearing knee examinations in the standing posture. This examination can assess cartilage loss and early osteoarthritis. As biomechanical studies have shown that the tibiofemoral contact stress is greatest with the knee flexed, standing views are obtained with the knee pressed against the table. A table tilt of 70 degrees is used with a waist restraint for safety.

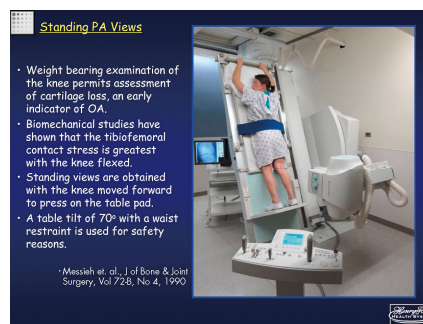


Fig. 17

Lateral radiographs of the knee are conducted with the foot raised onto the edge of the foot stand (**Fig. 18**). The table tilt of 60 degrees places a similar load on the single leg to that when standing normally on two legs.

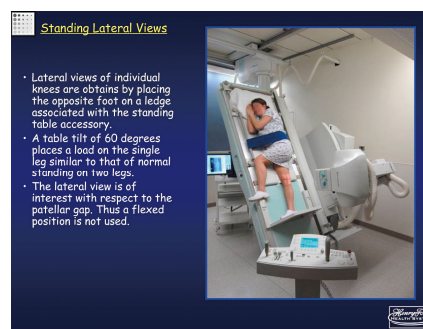


Fig. 18

Coronal images of the knee in standing posture are taken at 2.5 mm slice thickness and 1 mm slice pitch with image reconstruction for 80 images normally taking 1 minute 30 seconds. Sagittal images also use the same slice thickness and slice pitch, with image reconstruction for 80 images normally taking 1 minute 30 seconds.

3.3. Clinical Images

Case 1: Osteoarthritis (Fig. 19)

Tomosynthesis images under gravitational load show bone-to-bone contact at the medial femoral condyle, which is hidden in radiographs. In addition, the additional spatial information allows accurate assessment of changes in arthritis.

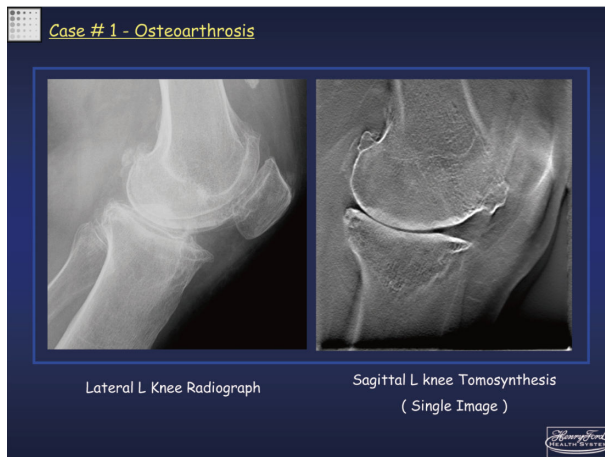
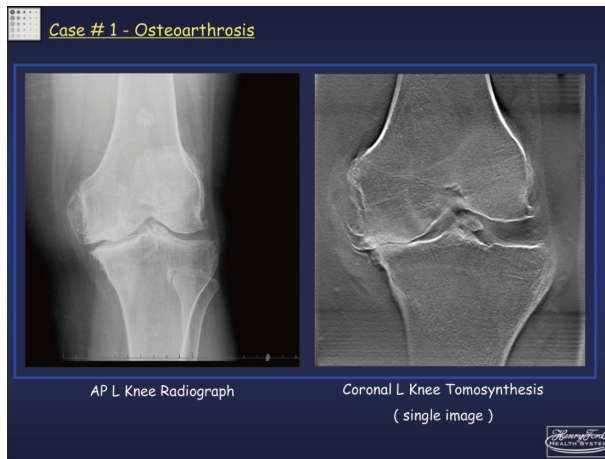


Fig. 19

Case 2: Sudden Onset Left Knee Pain (Fig. 20)

In this case, initially no abnormality could be seen in the frontal and lateral radiographs but MRI follow-up images reveal insufficiency fractures in the medial femoral condyle and lateral femoral condyle. Similarly, tomosynthesis discovers the cracks but offers much higher spatial resolution and greater utility than MRI.

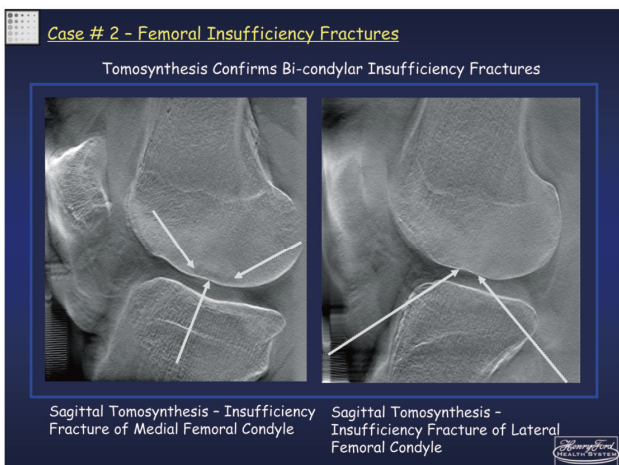
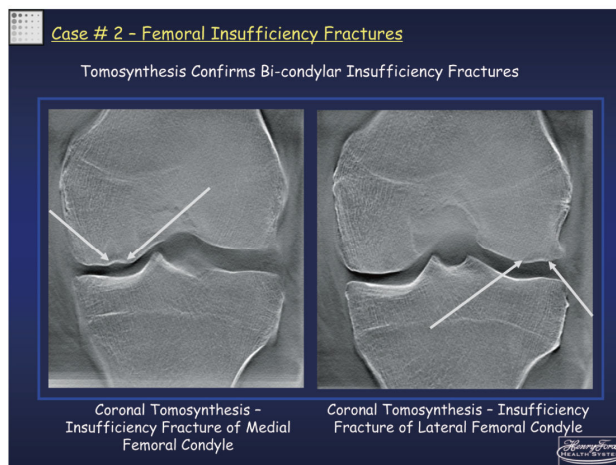
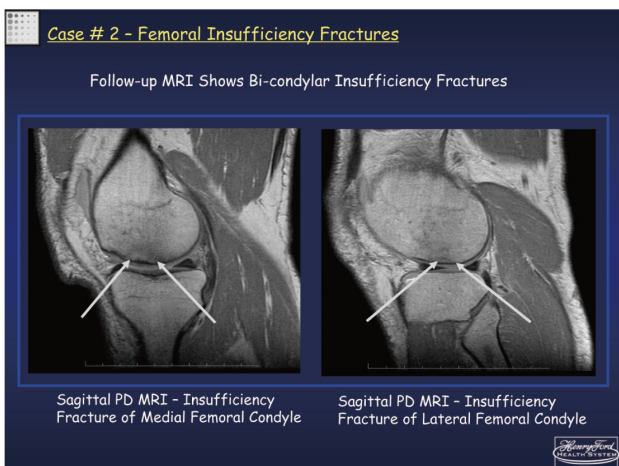
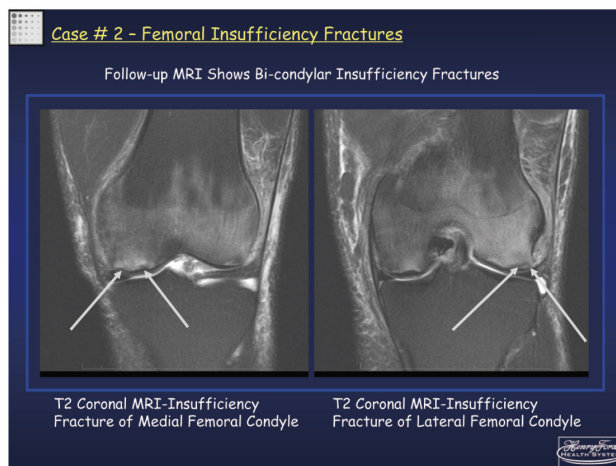
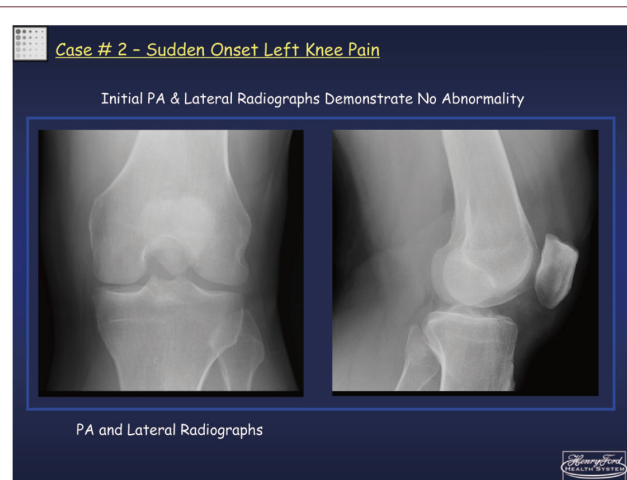


Fig. 20

Case 3: Tibial Plateau Fracture (Fig. 21)

After an initial CT evaluation, the healed fracture remained painful. Follow up by tomosynthesis after one year revealed a residual step-off deformity that was believed to be the cause of the pain.

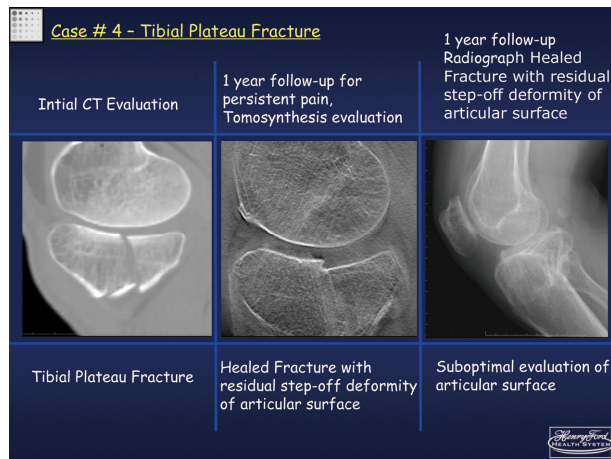


Fig. 21

4. Clinical Images at a SEAAPM Educational Symposium

The tomosynthesis cases presented by Dr. Flynn were introduced at an educational symposium held by the SEAAPM (Southeast Chapter of the American Association of Physicists in Medicine) in March 2007.

Case 4: Suspected Trochanter Fracture (Fig. 22)

While not identifiable in radiographs, the edema apparent in the MR image suggests the need for surgery. However, tomosynthesis showed that the fracture was restricted to the non-weight-bearing head of the trochanter, so that surgery was not required.

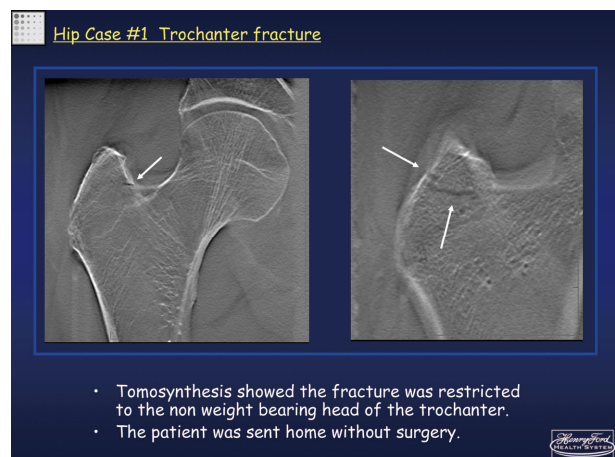
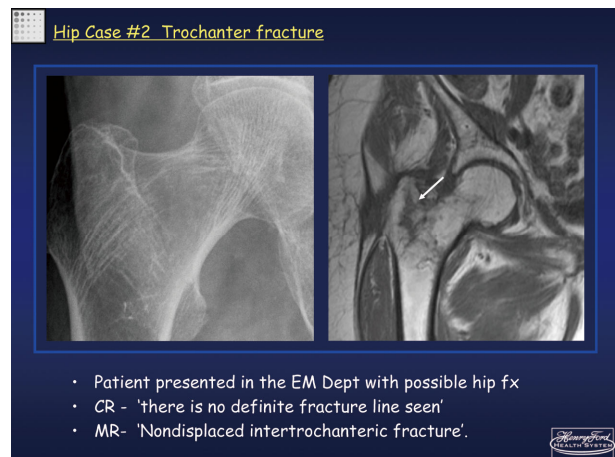


Fig. 22

5. Conclusions

This paper introduced the evaluation of tomosynthesis using SONIALVISION safire based on the presentation by Dr. Flynn of Henry Ford Health System at RSNA 2006 and using the clinical images displayed in the Henry Ford Health System Corner in the Shimadzu booth at RSNA 2006 and presented by Dr. Flynn at the SEAAPM educational symposium.

In the future, Shimadzu intends to further expand the utility and possibilities of tomosynthesis.